

Amygdala and regional volumes in treatment-resistant *versus* non-treatment-resistant depression patients

Anca-Larisa Sandu^{1,2}, Eric Artiges^{1,3}, André Galinowski¹, Thierry Gallarda⁴, Frank Bellivier⁵, Hervé Lemaître¹, Bernard Granger⁶, Damien Ringuenet⁷, Eleni T. Tzavara^{1,6,8}, Jean-Luc Martinot¹, Marie-Laure Paillère Martinot^{1,9}

Institutions:

¹ Institut National de la Santé et de la Recherche Médicale, INSERM Unit 1000 "Neuroimaging & Psychiatry", University Paris Sud-Paris Saclay, University Paris Descartes, Service Hospitalier Frédéric Joliot, Orsay, France

² Aberdeen Biomedical Imaging Centre, Lilian Sutton Building, University of Aberdeen, UK

³ Department of Psychiatry 91G16, Orsay Hospital, Orsay, France

⁴SHU Sainte-Anne Hospital, Paris, France

⁵APHP Department of Psychiatry, Fernand Widal Hospital, Paris, France

⁶APHP Department of Psychiatry, Tarnier Hospital, & University Paris Descartes Paris, France

⁷Service de Psychiatrie et Addictologie, Hôpital Paul Brousse, APHP Villejuif, France

⁸Institut National de la Santé et de la Recherche Médicale, INSERM Unit 1130, UPMC, Paris, France

⁹INSERM Unit 1000 at Maison de Solenn, Paris, France

¹⁰ AP-HP Adolescents Psychopathology and Medicine Department, Maison de Solenn, Cochin Hospital and University Paris Descartes, Paris, France.

Short title: Amygdala in treatment-resistant depression

Key words: Depression, Brain Imaging/Neuroimaging, Treatment Resistance, biological markers, Bipolar disorder

Disclosure statement: Dr. Paillère Martinot reports personal fees from Janssen, not related to the submitted work. The rest of the authors have nothing to disclose.

Author responsible for correspondence:

Anca-Larisa Sandu, Aberdeen Biomedical Imaging Centre, Lilian Sutton Building, University of Aberdeen, Foresterhill, AB25 2ZD Aberdeen, UK; email: anca.sandu-giuraniuc@abdn.ac.uk

Abstract

BACKGROUND: While treatment-resistant and non-treatment-resistant depressed patients show structural brain anomalies relative to healthy controls, the difference in regional volumetry between these two groups remains undocumented.

METHODS: A whole-brain voxel-based morphometry (VBM) analysis of regional volumes was performed in 125 participants' MR images obtained on a 1.5 Tesla scanner; 41 had treatment-resistant depression (TRD), 40 non-treatment-resistant depression (non-TRD), and 44 were healthy controls. The groups were comparable for age and gender. Bipolar/unipolar features as well as pharmacological treatment classes were taken into account as covariates.

RESULTS: TRD patients had higher gray matter (GM) volume in the left and right amygdala than non-TRD patients. No difference was found between the TRD bipolar and the TRD unipolar patients, or between the non-TRD bipolar and non-TRD unipolar patients. An exploratory analysis showed that lithium-treated patients in both groups had higher GM volume in the superior and middle frontal gyri in both hemispheres.

CONCLUSIONS: Higher gray matter volume in amygdala detected in TRD patients might be seen in perspective with vulnerability to chronicity, revealed by medication resistance.

Introduction

Treatment-resistant depression occurs in 20% to 30% of depressed patients and leads to severe disability (Greden 2001). Treatment-resistant depression (TRD) is a condition in which the patients fail to respond to at least two trials with antidepressants from different pharmacological classes or do not evolve favourably under the influence of the treatment (Little 2009, Duhameau et al. 2010, Kubitz et al. 2013). Although Major Depressive Disorder (MDD) has been scrutinized by neuroimaging studies (Konarski et al. 2006, Koolschijn et al. 2009, Lorenzetti et al. 2009, Price, Drevets 2010), fewer magnetic resonance (MR) studies have examined the brain structure in TRD *versus* non-treatment-resistant depression (non-TRD) (McIntyre et al. 2014).

Smaller gray matter volume in several frontal and temporal regions, may confer vulnerability to or characterize patients with TRD (Furtado, Maller & Fitzgerald 2008, Li et al. 2010, Shah et al. 1998, Shah et al. 2002). Larger GM volumes have also been observed, notably in the temporal cortex regions, including the parahippocampus and amygdala (Li et al. 2010), although this has not been constantly replicated (Zhou et al. 2011). Further MR brain morphometry analysis is warranted given the scarcity of studies of these latter regions involved in emotional regulation.

Indeed, other MR modalities in TRD patients suggest changes in amygdala and related regions. Higher resting-state hippocampus-amygdala blood flow was found in TRD patients compared to patients with non-TRD in a single photon emission computed tomography study (SPECT) (Hornig, Mozley & Amsterdam 1997). Furthermore, arterial spin labelling perfusion MRI showed *hyperperfusion* in the TRD and chronically depressed patients, in the left subcortical regions (amygdala, putamen and pallidum), together with the left dorsomedial prefrontal, left anterior cingulate cortex (ACC) (Duhameau et al. 2010). Also, reduced functional connectivity within the left amygdala to anterior cingulate was reported, when comparing TRD to non TRD (Lui et al. 2011). Reduced magnetization transfer ratio was observed in the amygdala-parahippocampal areas, caudate, anterior cingulate, and insula, in the right hemisphere, in the TRD group relative to healthy controls, but voxel-based morphometry (VBM) analyses did not reveal any morphological difference between these groups (Zhang et al. 2009).

The involvement of specific brain regions in TRD was furthermore suggested by the improvement of clinical conditions obtained through repetitive transcranial magnetic stimulation in dorsolateral prefrontal cortex (Paillere Martinot et al. 2011) or through deep brain stimulation in subcallosal cingulate (Holtzheimer, Mayberg 2010).

Thus the pathogenesis of TRD is still under debate; it could have structural (Li et al. 2010) and/or functional determinants being attributed to abnormal neural activity in multiple brain regions (Lui et al. 2011, Guo et al. 2011, Kumari et al. 2003). Notably, abnormalities in limbic regions may play a role in the pathophysiology of treatment-resistance (Hornig, Mozley & Amsterdam 1997), in the foreground of which the amygdala - hippocampus complex.

There is a limited number of studies regarding the differences of brain morphometry between TRD and non-TRD patients (McIntyre et al. 2014) and even inconsistencies of findings (Shah et al. 2002, Zhou et al. 2011), that were sometimes driven by a region of interest approach. Based on a previous study by our group (Paillere Martinot et al. 2011) reporting higher fluoro-deoxyglucose metabolism (FDG) in the amygdala associated with decreased FDG in the orbitofrontal cortex in TRD patients resistant to repetitive transcranial magnetic stimulation, we searched for frontal-limbic structural abnormalities in TRD. The purpose of our study was to compare patients with TRD or non-TRD, and healthy controls using whole-brain voxel based morphometry (Ridgway et al. 2008, Ashburner, Friston 2000) of regional volumes.

Methods

The local ethics committees (APHP Salpêtrière and Bicêtre hospitals) approved the protocol of the study, and each participant provided written informed consent before inclusion in the studies.

Participants

We pooled datasets obtained from 125 participants enrolled in previous brain imaging protocols. Detailed demographic and clinical characteristics have been reported elsewhere (Paillere Martinot et al.

2011, Penttila et al. 2009). Briefly, we recruited patients from consecutive admissions at an outpatient clinic and 6 psychiatry wards of university hospitals in Paris, France. Experienced senior psychiatrists established the patients' diagnoses using the DSM-IV and the Mini- International Neuropsychiatric Interview. We also recruited healthy controls by word of mouth, and enrolled them at the same time as the patients. They had no personal history of psychiatric or neurological disorders, as assessed by the Mini-International Neuropsychiatric Interview and a medical examination.

Treatment-resistance was defined as the lack of response to at least 2 antidepressants from different pharmacologic classes taken for at least 1 month in adequate dosages (Berlim, Turecki 2007).

Non-TRD patients were in remission from a major depressive episode. Both unipolar and bipolar patients were considered in both TRD and non-TRD groups (Table 1).

At the time of scan most of the patients received treatment (74/81); they were taking antidepressant medications, anticonvulsants, lithium, antipsychotics, or benzodiazepines (Table 1). There were only 3 non-medicated patients in the TRD group and 4 in the non-TRD group during data acquisition.

Image acquisition

Magnetic resonance imaging (MRI) high-resolution T1-weighted images were acquired with a 3D-MRI sequence (124 contiguous slices; field of view 24cm; 256x256 matrix; voxel size: $0.94 \times 0.94 \times 1.3 \text{ mm}^3$ or $0.86 \times 0.86 \times 1.2 \text{ mm}^3$), TE=2 ms, TR=10 ms, TI=600 ms, flip angle=10°, and read bandwidth=12.5 kHz on a 1.5 Tesla GE Signa scanner (General Electrics Medical Systems, Milwaukee, WI, USA).

Voxel-based morphometry

Data were processed and examined using the Statistical Parametric Mapping software (SPM8, <http://www.fil.ion.ucl.ac.uk/spm/software/spm8/>). To study the morphometric changes in the depression groups (responders and non-responders to the treatment) versus controls, VBM was performed using the unified segmentation implemented in SPM8 (Ashburner, Friston 2005). T1-weighted images were spatially normalized and segmented using the “new segmentation” toolbox with the extended tissues probability maps. Afterwards VBM implemented in the VBM8 toolbox was applied

(<http://dbm.neuro.uni-jena.de/vbm8/>) using clean-up segmentation and de-noising with non-local means filters for “write already estimated segmentation”.

Finally, the modulated GM images were smoothed with a Gaussian kernel of 10 mm full-width half-maximum (FWHM) isotropic Gaussian kernel.

Statistics

Demographic and clinical variables were analyzed within JMP software (<http://www.jmp.com>), using ANOVA, Khi2 or t tests as necessary.

Imaging data were analysed using SPM8 software and General Linear model. Voxel-wise GM differences between the patient groups and controls were examined using one way ANOVA. In order to answer to both primary and exploratory questions, the model included five groups (unipolar TRD, bipolar TRD, unipolar non-TRD, bipolar non-TRD, and healthy controls). Age, total intracranial volume (TIV), gender, voxel size, and the treatment (antidepressants, lithium, anticonvulsants used as mood stabilizers, antipsychotics, benzodiazepine) were entered in the analysis as covariates.

Primary analyses compared MDD (including TRD and non-TRD) patients versus controls, then TRD patients versus non-TRD patients. We also searched for differences between UP and BP TRD patients, and between UP and BP non-TRD patients respectively.

Secondary analyses explored the effect of treatments in the whole group of patients.

For all analyses height threshold was set at $p < 0.001$, and extent threshold at $p < 0.05$ (600 voxels) with family-wise error (FWE) correction for multiple spatial comparisons at the cluster level across the whole brain.

Results

Demographic and medication characteristics for subjects with MDD and healthy controls are reported in Table 1. TRD patients had significantly higher depression scores (MADRS) than non-TRD patients. Also, the non-TRD patients were more likely to have bipolar depression. No other between group difference was found, particularly regarding medications.

Primary analyses

The whole MDD patient group (vs control group) exhibited reduced GM volume in the right anterior cingulate (Table 2). Larger GM volume was found in bilateral amygdala in TRD patients as compared to non-TRD patients (Figure 1 and Table 2). No difference was found between UP and BP TRD patients, nor between UP and BP non-TRD patients.

Secondary analyses

The patients on lithium showed larger GM volumes in superior and middle frontal gyri bilaterally, when compared to patients not on lithium (Figure 2 and Table 2).

No significant difference was found with the other treatments.

Discussion

The comparison between patients with TRD and non-TRD motivated by the scarce information in the literature revealed a higher GM volume of the amygdala in the TRD patient group, while there was no difference in amygdala volumes between the whole depressed patient group and healthy controls. In addition, the greater amygdala volume in TRD patients was independent, irrespective of whether the patients presented bipolar or unipolar features. The depressed patients as a whole also exhibited reduced GM volume of the right anterior cingulate. The neurotrophic effect of the treatment with lithium was underlined once more by the current study showing higher GM volume in the superior and middle frontal gyri in the patients treated with lithium.

Herein, the reduction of GM volume in the right anterior cingulate in the whole MDD group, replicates the literature on MDD and anatomical MRI. The most consistent finding in MDD is indeed GM reduction in the anterior cingulate cortex (ACC) (Konarski et al. 2006, Caetano et al. 2006, Du et al. 2012, Tang et al. 2007, Treadway et al. 2009, Yucel et al. 2008). The evidence for reductions in other regions within fronto-subcortical and limbic regions is less consistently reported (Du et al. 2012, Bora et al. 2012). The current comparison consolidates once more the association between MDD and reduced

GM density in ACC, and supports Drevets et al.'s (1997) conclusion that despite treatment with antidepressant medication, the reduction in subgenual ACC volume still persists.

TRD is modelled as a failure of brain homeostatic mechanisms; the frontal lobes would be less active while the limbic regions, and notably the amygdala (involved in emotional processing and autonomic reactivity), would be overactive during depression (Giacobbe, Mayberg & Lozano 2009). Lui et al. (2011) found a higher connectivity in the TRD group with respect to the non-TRD within the left amygdala-anterior cingulate cortex-right insula-precuneus region. A seminal historical study (Hornig, Mozley & Amsterdam 1997) among the few that did a direct comparison between the TRD and non-TRD is also consistent with our findings of higher hippocampus-amygdala blood flow in TRD than in non-TRD patients. Here, the direct comparison between non-TRD and TRD groups highlights the difference in amygdala volume.

Amygdala, which plays a crucial role in modulating human emotion (Hamilton, Siemer & Gotlib 2008) has been extensively investigated with neuroimaging in affective disorders. Reviews of the literature, however, report the most conflicting findings depending on the stage of the disorder (Kubitz et al. 2013, Hamilton, Siemer & Gotlib 2008, Bellani, Baiano & Brambilla 2011). Only one VBM study in TRD patients has reported differences in amygdala volumes (Li et al. 2010). The authors found, in line with our results, a larger GM volume in the right amygdala, in the non-remitting patients when compared with those who achieved remission, although at a lenient, uncorrected statistical threshold.

Differences in regional brain volumes have previously been hypothesized between patients able to achieve remission and those refractory to antidepressants. A study found atrophy in the right frontostriatal region in TRD, but the authors did not attempt to measure amygdala separately and the treatment status was not controlled between the TRD and non-TRD patient groups (Shah et al. 2002).

In contrast with our results, Lorenzetti et al. (2010) found a larger left amygdala in *non-TRD* remitted MDD patients when compared to healthy controls, while other investigators showed a larger amygdala in the healthy control group when compared to MDD patients (Keller et al. 2008, Kronenberg et al. 2009). Another study has shown smaller hippocampal volumes in TRD patients relative to controls contrasting with our results that show no difference (Joshi et al. 2016). Interestingly in this study, smaller

hippocampal and larger amygdala volumes associated with response to subsequent ECT treatment, which further increased amygdala volume (Joshi et al. 2016, Ten Doesschate et al. 2014). Thus the question arises whether changes in amygdala volume in MDD are a trait characteristic of the disease or are related to disease progression, chronicity, or medication. Enlarged amygdala volumes have also been reported in first-episode depressed patients (van Eijndhoven et al. 2009), with a positive correlation with the severity of depression. However, both increased (Frodl et al. 2002, Frodl et al. 2003) and decreased (Bora et al. 2012) amygdala volumes have been reported in first-episode MDD. Thus, in perspective with this literature, our findings raise, *on one side*, the question whether larger amygdala volumes might indicate vulnerability to develop medication resistance, *on the other side*, changes in amygdala volumes might be a consequence of affective disease progression *per se*, (Bora et al. 2012, Singh, DelBello & Chang 2012).

Additionally, other factors that might influence amygdala volume include comorbid anxiety (Caetano et al. 2007) and medication, particularly mood stabilizers that are supposed to exert a neurotrophic effect (Price, Drevets 2010, Savitz et al. 2010). Meta-analytical studies by Hamilton, Siemer & Gotlib (2008) and Price and Drevets (2010) have indicated that studies focussing on only *non-medicated* depressed patients showed significantly lower amygdala volume in the depressed group when compared to controls, whereas studies in which all depressed patients were receiving adequate medication showed significantly larger amygdala volumes in the depressed group (Weniger, Lange & Irle 2006).

A particularity in the present study is that both groups (TRD and non-TRD) received treatment and one could hypothesise that the treatment received by TRD during recurrent episodes of illness may have had a cumulative neurotrophic effect reflected through a larger amygdala, even if the clinical features had not significantly improved. However, ongoing medication was included here as a covariate in the statistical analysis; thus it is unlikely that the findings would relate to medication only.

Furthermore, the finding of our exploratory comparison in patients (TRD and non TRD) treated with lithium vs patients without lithium advocates against a unique effect of medication on the amygdala volumes. We observed a higher GM volume in the superior and middle frontal gyri bilaterally, in patients

with lithium. Moore et al. (2009) also found a significant increase in GM volume in the prefrontal cortex related to lithium treatment. These results emphasize the purported neurotrophic effect of lithium (Quiroz et al. 2010), notably on the prefrontal cortex. However, the neurotrophic effect of lithium in the present study did not account for the higher GM volume in amygdala, since the comparison of lithium and non-lithium treated patients did not yield results in these regions.

Given the heterogeneous nature of depression (Wager, Woo 2017), it is possible that other factors that were not studied in our work may yet influence findings. For example, some recent work (Wager, Woo 2017, Drysdale et al. 2017) has shown that distinct depression connectivity biotypes may determine treatment responsiveness. Also, disease course (age of onset, number of depressive episodes) may contribute to variations in brain morphology. However, in our study no relation was found between age of onset or duration of illness, and amygdala volume.

Still, a main limitation of the present study is that it cannot disentangle whether the larger amygdala volume relates to vulnerability or develops through the course of the disease. Indeed, the cross sectional design of the study makes it difficult to determine whether a larger volume indicates a risk factor for TRD from the onset of illness, or whether it is a consequence of the failure of brain homeostatic mechanisms (e.g. overactive amygdala) related to comorbid anxiety during depression.

Also, patients with bipolar and unipolar depression were pooled in this study. Differences in amygdala volumes might have blurred the results, as larger amygdala volumes have been reported in adults with bipolar disorder (Strakowski 2012), while reduced amygdala volumes have been found in adolescent patients with bipolar disorder (Pfeifer et al. 2008). In the present study, however, there was no difference between the TRD BP patients and the TRD UP patients, and no difference between the non-TRD UP and BP patients, indicating a similar pattern regarding amygdala volumes in UP and BP patients.

Conclusions

Overall, this study found that TRD patients exhibit larger GM amygdala volumes. This increase was not related to medication or to bipolar or unipolar status, and might provide a neuroimaging biomarker of vulnerability to chronicity, revealed by medication resistance.

Acknowledgements

This study was supported by grant PHRC/AOM-98099 from the Assistance Publique-Hôpitaux de Paris (AP-HP) and the French Health Ministry; grant INSERM-PROGRES A99013LS from the French Institute for Health and Medical Research (INSERM), an AP-HP/INSERM interface grant (M-L Paillère-Martinot), and a JOIN APHP/INSERM grant (Eleni Tzavara).

References

- Ashburner, J. & Friston, K.J. 2005, "Unified segmentation", *NeuroImage*, vol. 26, no. 3, pp. 839-851.
- Ashburner, J. & Friston, K.J. 2000, "Voxel-based morphometry - The methods", *NeuroImage*, vol. 11, no. 6, pp. 805-821.
- Bellani, M., Baiano, M. & Brambilla, P. 2011, "Brain anatomy of major depression II. Focus on amygdala", *Epidemiology and psychiatric sciences*, vol. 20, no. 1, pp. 33-36.
- Berlim, M.T. & Turecki, G. 2007, "Definition, assessment, and staging of treatment-resistant refractory major depression: a review of current concepts and methods", *Canadian journal of psychiatry.Revue canadienne de psychiatrie*, vol. 52, no. 1, pp. 46-54.
- Bora, E., Harrison, B.J., Davey, C.G., Yucel, M. & Pantelis, C. 2012, "Meta-analysis of volumetric abnormalities in cortico-striatal-pallidal-thalamic circuits in major depressive disorder", *Psychological medicine*, vol. 42, no. 4, pp. 671-681.
- Caetano, S.C., Fonseca, M., Hatch, J.P., Olvera, R.L., Nicoletti, M., Hunter, K., Lafer, B., Pliszka, S.R. & Soares, J.C. 2007, "Medial temporal lobe abnormalities in pediatric unipolar depression", *Neuroscience letters*, vol. 427, no. 3, pp. 142-147.
- Caetano, S.C., Kaur, S., Brambilla, P., Nicoletti, M., Hatch, J.P., Sassi, R.B., Mallinger, A.G., Keshavan, M.S., Kupfer, D.J., Frank, E. & Soares, J.C. 2006, "Smaller cingulate volumes in unipolar depressed patients", *Biological psychiatry*, vol. 59, no. 8, pp. 702-706.

- Drevets, W.C., Price, J.L., Simpson, J.R., Jr, Todd, R.D., Reich, T., Vannier, M. & Raichle, M.E. 1997, "Subgenual prefrontal cortex abnormalities in mood disorders", *Nature*, vol. 386, no. 6627, pp. 824-827.
- Drysdale, A.T., Grosenick, L., Downar, J., Dunlop, K., Mansouri, F., Meng, Y., Fetcho, R.N., Zebley, B., Oathes, D.J., Etkin, A., Schatzberg, A.F., Sudheimer, K., Keller, J., Mayberg, H.S., Gunning, F.M., Alexopoulos, G.S., Fox, M.D., Pascual-Leone, A., Voss, H.U., Casey, B.J., Dubin, M.J. & Liston, C. 2017, "Resting-state connectivity biomarkers define neurophysiological subtypes of depression", *Nature medicine*, vol. 23, no. 1, pp. 28-38.
- Du, M.Y., Wu, Q.Z., Yue, Q., Li, J., Liao, Y., Kuang, W.H., Huang, X.Q., Chan, R.C., Mechelli, A. & Gong, Q.Y. 2012, "Voxelwise meta-analysis of gray matter reduction in major depressive disorder", *Progress in neuro-psychopharmacology & biological psychiatry*, vol. 36, no. 1, pp. 11-16.
- Duhameau, B., Ferre, J.C., Jannin, P., Gauvrit, J.Y., Verin, M., Millet, B. & Drapier, D. 2010, "Chronic and treatment-resistant depression: a study using arterial spin labeling perfusion MRI at 3Tesla", *Psychiatry research*, vol. 182, no. 2, pp. 111-116.
- Frodl, T., Meisenzahl, E., Zetsche, T., Bottlender, R., Born, C., Groll, C., Jager, M., Leinsinger, G., Hahn, K. & Moller, H.J. 2002, "Enlargement of the amygdala in patients with a first episode of major depression", *Biological psychiatry*, vol. 51, no. 9, pp. 708-714.
- Frodl, T., Meisenzahl, E.M., Zetsche, T., Born, C., Jager, M., Groll, C., Bottlender, R., Leinsinger, G. & Moller, H.J. 2003, "Larger amygdala volumes in first depressive episode as compared to recurrent major depression and healthy control subjects", *Biological psychiatry*, vol. 53, no. 4, pp. 338-344.
- Furtado, C.P., Maller, J.J. & Fitzgerald, P.B. 2008, "A magnetic resonance imaging study of the entorhinal cortex in treatment-resistant depression", *Psychiatry research*, vol. 163, no. 2, pp. 133-142.
- Giacobbe, P., Mayberg, H.S. & Lozano, A.M. 2009, "Treatment resistant depression as a failure of brain homeostatic mechanisms: Implications for deep brain stimulation", *Experimental neurology*, vol. 219, no. 1, pp. 44-52.

- Greden, J.F. 2001, "The burden of disease for treatment-resistant depression", *The Journal of clinical psychiatry*, vol. 62 Suppl 16, pp. 26-31.
- Guo, W.B., Sun, X.L., Liu, L., Xu, Q., Wu, R.R., Liu, Z.N., Tan, C.L., Chen, H.F. & Zhao, J.P. 2011, "Disrupted regional homogeneity in treatment-resistant depression: A resting-state fMRI study", *Progress in neuro-psychopharmacology & biological psychiatry*, vol. 35, no. 5, pp. 1297-1302.
- Hamilton, J.P., Siemer, M. & Gotlib, I.H. 2008, "Amygdala volume in major depressive disorder: a meta-analysis of magnetic resonance imaging studies", *Molecular psychiatry*, vol. 13, no. 11, pp. 993-1000.
- Holtzheimer, P.E. & Mayberg, H.S. 2010, "Deep Brain Stimulation for Treatment-Resistant Depression", *American Journal of Psychiatry*, vol. 167, no. 12, pp. 1437-1444.
- Hornig, M., Mozley, P.D. & Amsterdam, J.D. 1997, "HMPAO SPECT brain imaging in treatment-resistant depression", *Progress in neuro-psychopharmacology & biological psychiatry*, vol. 21, no. 7, pp. 1097-1114.
- Joshi, S.H., Espinoza, R.T., Pirnia, T., Shi, J., Wang, Y., Ayers, B., Leaver, A., Woods, R.P. & Narr, K.L. 2016, "Structural Plasticity of the Hippocampus and Amygdala Induced by Electroconvulsive Therapy in Major Depression", *Biological psychiatry*, vol. 79, no. 4, pp. 282-292.
- Keller, J., Shen, L., Gomez, R.G., Garrett, A., Solvason, H.B., Reiss, A. & Schatzberg, A.F. 2008, "Hippocampal and amygdalar volumes in psychotic and nonpsychotic unipolar depression", *The American Journal of Psychiatry*, vol. 165, no. 7, pp. 872-880.
- Konarski, J.Z., McIntyre, R.S., Soczynska, J.K., Bottas, A. & Kennedy, S.H. 2006, "Clinical translation of neuroimaging research in mood disorders", *Psychiatry (Edgmont (Pa.: Township))*, vol. 3, no. 2, pp. 46-57.
- Koolschijn, P.C., van Haren, N.E., Lensvelt-Mulders, G.J., HulshoffPol, H.E. & Kahn, R.S. 2009, "Brain Volume Abnormalities in Major Depressive Disorder: A Meta-Analysis of Magnetic Resonance Imaging Studies", *Human brain mapping*, vol. 30, no. 11, pp. 3719-3735.

- Kronenberg, G., Tebartz van Elst, L., Regen, F., Deuschle, M., Heuser, I. & Colla, M. 2009, "Reduced amygdala volume in newly admitted psychiatric in-patients with unipolar major depression", *Journal of psychiatric research*, vol. 43, no. 13, pp. 1112-1117.
- Kubitz, N., Mehra, M., Potluri, R.C., Garg, N. & Cossrow, N. 2013, "Characterization of Treatment Resistant Depression Episodes in a Cohort of Patients from a US Commercial Claims Database", *Plos One*, vol. 8, no. 10, pp. e76882.
- Kumari, V., Mitterschiffthaler, M.T., Teasdale, J.D., Malhi, G.S., Brown, R.G., Giampietro, V., Brammer, M.J., Poon, L., Simmons, A., Williams, S.C., Checkley, S.A. & Sharma, T. 2003, "Neural abnormalities during cognitive generation of affect in treatment-resistant depression", *Biological psychiatry*, vol. 54, no. 8, pp. 777-791.
- Li, C.T., Lin, C.P., Chou, K.H., Chen, I.Y., Hsieh, J.C., Wu, C.L., Lin, W.C. & Su, T.P. 2010, "Structural and cognitive deficits in remitting and non-remitting recurrent depression: A voxel-based morphometric study", *NeuroImage*, vol. 50, no. 1, pp. 347-356.
- Little, A. 2009, "Treatment-Resistant Depression", *American Family Physician*, vol. 80, no. 2, pp. 167-172.
- Lorenzetti, V., Allen, N.B., Fornito, A. & Yucel, M. 2009, "Structural brain abnormalities in major depressive disorder: a selective review of recent MRI studies", *Journal of affective disorders*, vol. 117, no. 1-2, pp. 1-17.
- Lorenzetti, V., Allen, N.B., Whittle, S. & Yucel, M. 2010, "Amygdala volumes in a sample of current depressed and remitted depressed patients and healthy controls", *Journal of affective disorders*, vol. 120, no. 1-3, pp. 112-119.
- Lui, S., Wu, Q., Qiu, L., Yang, X., Kuang, W., Chan, R.C., Huang, X., Kemp, G.J., Mechelli, A. & Gong, Q. 2011, "Resting-state functional connectivity in treatment-resistant depression", *The American Journal of Psychiatry*, vol. 168, no. 6, pp. 642-648.
- McIntyre, R.S., Filteau, M.J., Martin, L., Patry, S., Carvalho, A., Cha, D.S., Barakat, M. & Miguelez, M. 2014, "Treatment-resistant depression: definitions, review of the evidence, and algorithmic approach", *Journal of affective disorders*, vol. 156, pp. 1-7.

- Moore, G.J., Cortese, B.M., Glitz, D.A., Zajac-Benitez, C., Quiroz, J.A., Uhde, T.W., Drevets, W.C. & Manji, H.K. 2009, "A Longitudinal Study of the Effects of Lithium Treatment on Prefrontal and Subgenual Prefrontal Gray Matter Volume in Treatment-Responsive Bipolar Disorder Patients", *Journal of Clinical Psychiatry*, vol. 70, no. 5, pp. 699-705.
- Paillere Martinot, M.L., Martinot, J.L., Ringuenet, D., Galinowski, A., Gallarda, T., Bellivier, F., Lefaucheur, J.P., Lemaitre, H. & Artiges, E. 2011, "Baseline brain metabolism in resistant depression and response to transcranial magnetic stimulation", *Neuropsychopharmacology : official publication of the American College of Neuropsychopharmacology*, vol. 36, no. 13, pp. 2710-2719.
- Penttila, J., Cachia, A., Martinot, J.L., Ringuenet, D., Wessa, M., Houenou, J., Galinowski, A., Bellivier, F., Gallarda, T., Duchesnay, E., Artiges, E., Leboyer, M., Olie, J.P., Mangin, J.F. & Paillere-Martinot, M.L. 2009, "Cortical folding difference between patients with early-onset and patients with intermediate-onset bipolar disorder", *Bipolar disorders*, vol. 11, no. 4, pp. 361-370.
- Pfeifer, J.C., Welge, J., Strakowski, S.M., Adler, C.M. & DelBello, M.P. 2008, "Meta-analysis of amygdala volumes in children and adolescents with bipolar disorder", *Journal of the American Academy of Child and Adolescent Psychiatry*, vol. 47, no. 11, pp. 1289-1298.
- Price, J.L. & Drevets, W.C. 2010, "Neurocircuitry of mood disorders", *Neuropsychopharmacology : official publication of the American College of Neuropsychopharmacology*, vol. 35, no. 1, pp. 192-216.
- Quiroz, J.A., Machado-Vieira, R., Zarate, C.A., Jr & Manji, H.K. 2010, "Novel insights into lithium's mechanism of action: neurotrophic and neuroprotective effects", *Neuropsychobiology*, vol. 62, no. 1, pp. 50-60.
- Ridgway, G.R., Henley, S.M., Rohrer, J.D., Scahill, R.I., Warren, J.D. & Fox, N.C. 2008, "Ten simple rules for reporting voxel-based morphometry studies", *NeuroImage*, vol. 40, no. 4, pp. 1429-1435.
- Savitz, J., Nugent, A.C., Bogers, W., Liu, A., Sills, R., Luckenbaugh, D.A., Bain, E.E., Price, J.L., Zarate, C., Manji, H.K., Cannon, D.M., Marrett, S., Charney, D.S. & Drevets, W.C. 2010,

- "Amygdala volume in depressed patients with bipolar disorder assessed using high resolution 3T MRI: the impact of medication", *NeuroImage*, vol. 49, no. 4, pp. 2966-2976.
- Shah, P.J., Ebmeier, K.P., Glabus, M.F. & Goodwin, G.M. 1998, "Cortical grey matter reductions associated with treatment-resistant chronic unipolar depression. Controlled magnetic resonance imaging study", *The British journal of psychiatry : the journal of mental science*, vol. 172, pp. 527-532.
- Shah, P.J., Glabus, M.F., Goodwin, G.M. & Ebmeier, K.P. 2002, "Chronic, treatment-resistant depression and right fronto-striatal atrophy", *The British journal of psychiatry : the journal of mental science*, vol. 180, pp. 434-440.
- Singh, M.K., DelBello, M.P. & Chang, K.D. 2012, "Neuroimaging studies of bipolar disorder in youth" in *The bipolar brain. Integrating neuroimaging and genetics*, ed. S.M. Strakowski, Oxford University press: New York, USA, 2012, , pp. 103-123.
- Strakowski, S.M. 2012, "Integration and consolidation - a neurophysiological model of bipolar disorder" in *The bipolar brain: Integrating Neuroimaging and Genetics*, ed. S.M. Strakowski, Oxford University Press, New York, , pp. 253-274.
- Tang, Y., Wang, F., Xie, G., Liu, J., Li, L., Su, L., Liu, Y., Hu, X., He, Z. & Blumberg, H.P. 2007, "Reduced ventral anterior cingulate and amygdala volumes in medication-naive females with major depressive disorder: A voxel-based morphometric magnetic resonance imaging study", *Psychiatry Research-Neuroimaging*, vol. 156, no. 1, pp. 83-86.
- Ten Doesschate, F., van Eijndhoven, P., Tendolkar, I., van Wingen, G.A. & van Waarde, J.A. 2014, "Pre-treatment amygdala volume predicts electroconvulsive therapy response", *Frontiers in psychiatry*, vol. 5, pp. 169.
- Treadway, M.T., Grant, M.M., Ding, Z., Hollon, S.D., Gore, J.C. & Shelton, R.C. 2009, "Early adverse events, HPA activity and rostral anterior cingulate volume in MDD", *PloS one*, vol. 4, no. 3, pp. e4887.
- van Eijndhoven, P., van Wingen, G., van Oijen, K., Rijpkema, M., Goraj, B., Verkes, R.J., Oude Voshaar, R., Fernandez, G., Buitelaar, J. & Tendolkar, I. 2009, "Amygdala Volume Marks

- the Acute State in the Early Course of Depression", *Biological psychiatry*, vol. 65, no. 9, pp. 812-818.
- Wager, T.D. & Woo, C.W. 2017, "Imaging biomarkers and biotypes for depression", *Nature medicine*, vol. 23, no. 1, pp. 16-17.
- Weniger, G., Lange, C. & Irle, E. 2006, "Abnormal size of the amygdala predicts impaired emotional memory in major depressive disorder", *Journal of affective disorders*, vol. 94, no. 1-3, pp. 219-229.
- Yucel, K., McKinnon, M.C., Chahal, R., Taylor, V.H., Macdonald, K., Joffe, R. & MacQueen, G.M. 2008, "Anterior cingulate volumes in never-treated patients with major depressive disorder", *Neuropsychopharmacology : official publication of the American College of Neuropsychopharmacology*, vol. 33, no. 13, pp. 3157-3163.
- Zhang, T.J., Wu, Q.Z., Huang, X.Q., Sun, X.L., Zou, K., Lui, S., Liu, F., Hu, J.M., Kuang, W.H., Li, D.M., Li, F., Chen, H.F., Chan, R.C., Mechelli, A. & Gong, Q.Y. 2009, "Magnetization transfer imaging reveals the brain deficit in patients with treatment-refractory depression", *Journal of affective disorders*, vol. 117, no. 3, pp. 157-161.
- Zhou, Y., Qin, L.D., Chen, J., Qian, L.J., Tao, J., Fang, Y.R. & Xu, J.R. 2011, "Brain microstructural abnormalities revealed by diffusion tensor images in patients with treatment-resistant depression compared with major depressive disorder before treatment", *European Journal of Radiology*, vol. 80, no. 2, pp. 450-454.

Table 1: Demographic and medication characteristics for subjects with MDD and healthy controls

Demographic and medication characteristics	MDD patients N=81		Healthy subjects N=44	p
	TRD N=41	Non-TRD N=40		
Age (years), mean \pm SD	47.15 \pm 8.06	46.10 \pm 9.62	46.42 \pm 10.08	0.87
Age range, years	29 - 59.5	29 - 63	28.5 - 62	
Gender , male, N (%)	15 (36.59)	22 (55.00)	23 (52.27)	0.19
Age of Onset , mean \pm SD	28.26 \pm 9.92	28.06 \pm 10.90	-	0.93
Duration of Illness , mean \pm SD	18.90 \pm 9.21	18.01 \pm 11.56	-	0.71
MADRS , mean \pm SD	34.20 \pm 7.19	12.70 \pm 13.78	-	<0.001
Unipolar depression N (%) ¹	26 (63.41)	16 (40.00)	-	
Bipolar depression , N (%) ²	15 (36.59)	24 (60.00)	-	0.03
Antidepressants/SSRIs N (%)	19 (46.34)	23 (57.50)	-	0.31
Anticonvulsants N (%)	12 (29.27)	10 (25.00)	-	0.67
Lithium N (%)	5 (12.20)	10 (25.00)	-	0.14
Antipsychotics N (%)	16 (39.02)	9 (22.50)	-	0.11
Benzodiazepine N (%)	18 (43.90)	15 (37.50)	-	0.56

¹ TRD unipolar patients (34.6 % male, mean age 45.4 \pm 9.3); non-TRD unipolar patients (50% male, mean age 42.3 \pm 7.53)

² TRD bipolar patients (40.00 % male, mean age 45.7 \pm 6.32); non-TRD bipolar patients (58.3% male, mean age 48.6 \pm 10.15)

Abbreviations: SD, standard deviation; SSRIs, selective serotonin reuptake inhibitors; MDD, Major depressive disorder; TRD, treatment resistant depression; p, p value (ANOVA, Khi2 or t test)

Table 2: Regional gray matter density differences in whole-brain voxel-based comparisons.

Region	Side	Cluster		Peak level				
		k	p FWE	MNI coordinates			p ^a	t
		x	y	z				
TRD > non-TRD								
Amygdala	Right	1145	0.006	28	4	-20	2.32E-06*	4.82
Superior temporal gyrus	Right			40	-1	-15	5.87E-06	4.59
Amygdala	Left	791	0.029	-34	2	-18	1.92E-05	4.35
HC > MDD								
Anterior Cingulate	Right	659	0.052	2	34	19	5.85E-06	4.59
BP TRD vs UP TRD		No suprathreshold voxel in any comparison						
BP nonTRD vs UP nonTRD		No suprathreshold voxel in any comparison						
Li > non-Li								
Middle/Superior frontal gyrus	Left	2746	<0.001	-21	53	31	5.66E-07*	5.15
Superior Frontal /Sub-gyral	Left			-22	9	45	1.55E-06*	4.92
Middle frontal gyrus	Left			-27	54	24	1.75E-06*	4.89
Middle frontal gyrus	Right	1977	<0.001	45	23	37	5.62E-06	4.60
Middle/Superior frontal gyrus	Right			38	17	54	1.82E-05	4.30
Middle frontal gyrus	Right			39	2	54	1.92E-05	4.29

Abbreviations: TRD > non-TRD, comparison between treatment-resistant and non-resistant depression groups; HC > MDD, comparison between healthy controls and major depressive disorder patients (TRD and non TRD); BP, bipolar; UP, unipolar; Li > non-Li, comparison between MDD patients treated with lithium and patients without lithium; k = cluster size, expressed in number of voxels ; MNI = Montreal neurological Institute coordinates in millimeters; MNI coordinates are given for the voxel of maximal statistical; t, Student test value.

p FWE. Cluster extent threshold $p < 0.05$ Family Wise Error (FWE) corrected

p^a. Height threshold $p < 0.001$ uncorrected; * Height threshold $p < 0.05$ Family Wise Error (FWE) corrected.

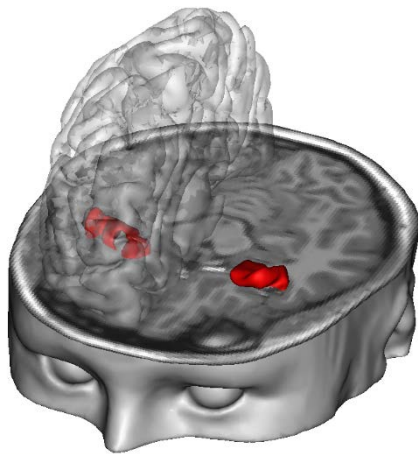


FIGURE 1 Whole-brain voxel-based morphometry (VBM) comparison between treatment-resistant (TRD) patients and non-resistant depression (non-TRD). TRD patients show higher gray matter volume in amygdala (red). Images are presented with height threshold $P < 0.001$ and FWE correction for multiple spatial comparisons across the whole brain

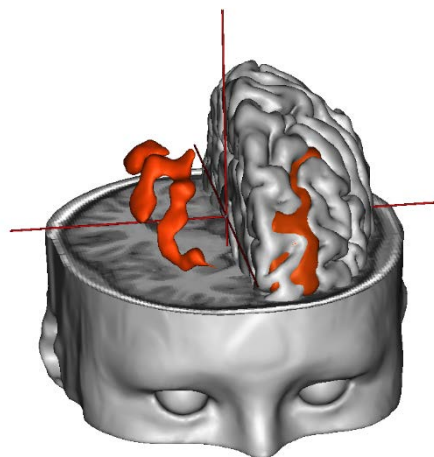


FIGURE 2 Whole-brain voxel-based morphometry (VBM) comparison between patients (TRD and not TRD) treated with lithium and patients without lithium. Lithium-treated patients show higher gray matter volume (red) in the superior and middle frontal gyri, bilaterally, when compared with patient group without lithium. Images are displayed with height threshold $P < 0.001$, and FWE correction for multiple spatial comparisons across the whole brain