

Intravitreal Aflibercept for Retinal Angiomatous Proliferation. Ninety Six week results of a prospective case series.

Andrew C. Browning¹, Jill M. O'Brien¹, Rute V. Vieira², Rajen Gupta¹, Kapka Nenova¹,

1) Newcastle Eye Centre, Royal Victoria Infirmary, Newcastle upon Tyne, NE1 4LP, UK

2) Institute of Applied Health Sciences, Polwarth Building, University of Aberdeen, Aberdeen, UK, AB25 2ZD

Corresponding author: Andrew C Browning, Newcastle Eye Centre, Royal Victoria Infirmary, Newcastle upon Tyne, NE1 4LP

Tel no +44 191 2820474

Fax No +44 191 2826269

e-mail: andrew.browning@nuth.nhs.uk

Introduction: Retinal angiomatous proliferation (RAP) is a subtype of neovascular age-related macular degeneration (nAMD). Untreated, the lesions are thought to be aggressive and lead to a poor visual outcome. Despite some limitations, studies reporting the treatment of RAP lesions with the intravitreal anti-VEGF drugs ranibizumab and bevacizumab have demonstrated variable but generally favourable responses. More recently, aflibercept has been licenced for the treatment of nAMD and may offer some advantages over other agents. We present the 96 week visual and anatomical outcomes of patients with RAP lesions treated with intravitreal Aflibercept, using the pivotal VIEW study nAMD treatment protocol.

Methods: This is a prospective study of treatment naïve patients with reading centre graded RAP lesions. The patients received aflibercept every 8 weeks after 3 initial monthly injections up to and including week 48. From weeks 52 to 96 patients received injections at least every 12 weeks with monthly evaluations for interim injections if they fulfilled the retreatment criteria. At each visit, best corrected visual acuity (BCVA) and optical coherence tomography (OCT) central macular thickness (CMT) was measured.

Results: Forty six patients reached study completion at week 96. Mean BCVA improved by 6.0 (SD=7.9) and 4.8 (SD=7.4) ETDRS letters at 52 (p=0.003) and 96 (p=0.02) weeks respectively, from a baseline of 57.3 (SD=12.0) letters. At the 52 and 96 week time points, 45/46 (98%) and 41/46 (89%) of patients respectively, had maintained their vision (less than 15 letters of BCVA lost). At the 96 week time point, 13/46 (28%) of patients had gained 15 letters or more and also demonstrated a mean reduction in CMT of 162 microns (SD=106) (p=<0.0001), with 72 % of maculae being fluid free. Using univariate analysis, we found no significant difference between any of the visual outcomes measures of the current study and the pivotal View study. The mean number of injections required and the mean change in CMT in each study was also similar.

Conclusions: In this study, we present the 96 week results of the largest series to date of patients treated prospectively with aflibercept for RAP using the VIEW protocol and show that they benefit from treatment to a similar degree to those with type 1 and 2 nAMD.

Retinal angiomatous proliferation (RAP) is a distinct form of neovascular age-related macular degeneration (nAMD), first described by Yanuzzi in 2001¹ and later revised by Freund in 2008 with the entity being reclassified as type 3 neovascularisation in recognition of it being of a different pathological mechanism compared with type 1 and 2 neovascularisation (occult and classic lesions respectively)². The disorder is thought to occur in approximately 15-20 % of cases of nAMD^{2,3} and is characterised by initial intraretinal neovascularisation⁴. Compared with type 1 and 2 choroidal neovascularisation, risk factors for RAP are thought to include older age, arterial hypertension, the ARMS2 gene risk allele, female sex and the presence of reticular pseudodrusen^{3,5-9}. Untreated, RAP lesions are thought to be aggressive and to have a poor visual outcome¹⁰. There also appears to be an increased rate of second eye involvement with up to 100% of fellow eyes being similarly affected within 3 years^{9,11}. Workers have previously treated RAP lesions by direct laser photocoagulation, Verteporfin photodynamic therapy alone and in combination with intravitreal triamcinolone all with limited long term success¹²⁻¹⁷. More recently, treatment with the intravitreal anti-VEGF drugs ranibizumab and bevacizumab have demonstrated generally favourable but variable responses¹⁸⁻²³. Unfortunately, many of these studies were limited by variable treatment and follow up protocols and were often retrospective in nature. More recently, aflibercept has been licensed to treat nAMD after the results of the pivotal VIEW studies were published^{24,25}. The drug demonstrated clinical equivalence with ranibizumab and because of its higher binding affinity for VEGF, offers the potential benefit of less frequent treatment and follow up visits. To date, very little data has been presented on the long term effectiveness of Aflibercept in treating RAP lesions, with the few studies being limited by short follow up and small patient numbers²⁶⁻²⁸. We present the 96 week results of patients with reading centre graded RAP lesions, treated with intravitreal Aflibercept using the treatment and follow up protocols of the pivotal VIEW studies.

Materials and methods

This was a prospective, interventional single centre study on patients with macular RAP lesions who presented to the macular clinic of one of the authors (ACB) and were naïve to treatment. Consecutive patients were recruited to the study if they fulfilled the NICE guidance for the treatment of nAMD with Aflibercept (TA294)²⁹. Briefly they were required to have an age greater than 50 years, a best-corrected visual acuity (BCVA) between 73 and 25 ETDRS letters (6/12 and 6/96), there had to be no permanent structural damage to the central fovea, the lesion size had to be less than or equal to 12 disc areas in greatest linear dimension and there had to be evidence of recent presumed disease progression, as indicated by fluorescein angiography, or recent visual acuity changes ^{29,30}.

A diagnosis of RAP was made if there was a focal area of intense intraretinal hyper fluorescence (hot spot) in the early phase of the fluorescein angiogram (FA) and a hot spot corresponding to the neovascular lesion that became increasingly hyper fluorescent during the mid and late phases of the indocyanine green (ICG) angiogram, along with one or more of the following: focal intra retinal superficial haemorrhages, lipid, fibrovascular pigment epithelial detachment and retinal vascular abnormality such as an anastomosis between retinal vessels or between retinal and choroidal vessels or retinal vessels with the underlying CNV complex ^{1,2,18,22,31}. The diagnosis was confirmed and the RAP lesions were graded by the Central Angiographic Resource Facility, Queen's University, Belfast, UK, based on stereo colour photographs (Carl Zeiss, Cambridge, UK), stereo FA and ICG angiograms (HRA2, Heidelberg Engineering, Heidelberg, Germany) and macular OCT scans (Spectralis, Heidelberg Engineering, Heidelberg, Germany) ^{1,2,9,32}. The patients were treated using the VIEW 2q8 protocol as this has been shown to be effective in a phase 3 randomised controlled trial for the treatment of nAMD ^{24,25}. This allows for a direct comparison to be made between the response of the RAP lesions in the current study and the type 1 and 2 lesions found in the VIEW study³³.

No patient presented with simultaneous bilateral RAP lesions. Only the first eye was included in the study if they subsequently went on to develop a lesion in the fellow eye during the follow up period. The patients received 2mg of intravitreal Aflibercept (Bayer, basal, Switzerland) every 8 weeks after 3 initial monthly injections up to and including week 48. From weeks 52 to 96 patients received injections at least every 12 weeks with monthly evaluations for interim injections if there was new or persistent fluid on OCT scan, an increase in central macular thickness (CMT) of 100 microns or more, a loss of 5 ETDRS letters or more in conjunction with recurrent fluid on OCT, new macular haemorrhage or a time lapse of 12 weeks since the previous injection (capped prn protocol)²⁵. At the baseline visit, patient demographics and past ocular history was recorded. The BCVA was recorded in both eyes using ETDRS charts at 2 metres as previously described³⁴. The macula was evaluated by indirect ophthalmoscopy and OCT scans using a fast macula scan. The baseline OCT scan was used as the reference scan for subsequent visits using Heidelberg registration software. A 30 degree 488nm macular blue fundus autofluorescence (FAF) image was recorded at baseline and then every 6 months (Spectralis, Heidelberg Engineering, Heidelberg, Germany). At each subsequent visit, BCVA was recorded, indirect ophthalmoscopy performed and a macular OCT scan was performed with reference to the baseline registration scan. The presence of reticular pseudodrusen baseline was determined by one of the authors (ACB) based on previous methods using a combination of OCT, infra-red reflectance and fundus autofluorescence^{35,36}. Sub-foveal choroidal thickness (SFCT) was measured at baseline in the affected eyes using the fast macular scan in enhanced depth imaging (EDI) mode by 2 independent examiners (RG and JMO) who were masked to the patient's demographics or outcomes. The SFCT was defined as the mean measurement from the outer aspect of BM to the inner surface of sclera using callipers within the Heidelberg software on magnified OCT horizontal scans passing through fovea. An aged matched control group of Caucasian patients undergoing cataract surgery with AREDS category 1 AMD or less³⁷ and who had normal axial lengths (22.0-24.5mm) were used to establish a local normal range for SFCT. The left eyes of the control subjects were used to calculate the age matched normal range.

The study was approved by the local research ethics committee and adhered to the tenets of the Declaration of Helsinki.

Outcome measures

Similar to the VIEW study, the primary end point was the number of patients maintaining visual acuity (losing less than 15 ETDRS letters at weeks 52 and 96). Secondary end points were: the proportion of patients gaining 15 letters or more at weeks 52 and 96, the mean change in central retinal thickness from baseline through to week 96, the proportion of patients without retinal fluid at weeks 52 and 96 and the mean number of study drug injections up to week 96.

Statistical analysis

Results from this study were compared with those of the published outcomes from the VIEW2 2q8 arm of the pivotal VIEW studies^{24,25}. The Student's paired t-test was used to compare the differences between BCVA or CMT at baseline and other time points and the Student's unpaired t-test was used for comparing the differences between axial lengths and SFCT in the patient and control groups. As recommended by Peduzzi et al³⁸, we followed the rule of including one covariate in the model for each 10 outcome events, which only allowed us to perform univariate logistic regression analyses to investigate the relationship between individual aspects of the patients' baseline demographics and a favourable visual outcome (greater than 15 ETDRS letters gained). The results of this analyses were presented as odds ratios and 95% confidence intervals and statistical significance was assumed when the confidence interval (CI) of the odds ratio (OR) included 1. The proportions of individuals with a loss of 15 letters or more at 52 and 96 weeks and gain of 15 letters or more at 52 and 96 weeks were compared between this study and the VIEW study using Fisher's exact test. Data analysis as performed using SPSS version 22 and R version 3.5.1.

Results

In total, 53 patients fulfilled the inclusion criteria and were recruited to the study between January 2014 and August 2015. Seven patients withdrew early (4 due to serious illness, 2 due to endophthalmitis and 1 death). Neither of the patients who developed endophthalmitis had any predisposing factors and the departmental rate at the time of the study was less than 0.033%. Forty six patients reached study completion at week 96. The patients that completed the study were all Caucasian, with a mean age of 81.5 years (range 67 to 97). There were 34 females (74%) and 29 left eyes (63%). Table 1 compares the baseline demographics of the patients in the current study with those of the 2q8 treatment arm of the VIEW study. At baseline, 7 patients were diabetic (15%), 10 were current smokers (22%), 27 were on treatment for hypertension (59%), 5 were taking clopidogrel (11%) and 18 eyes were pseudophakic (39%). The mean symptom duration prior to initiation of treatment was 7.8 weeks (range 4 days to 52 weeks). In the affected eye, 39/46 (85%) of maculae had evidence of reticular pseudodrusen, the mean SFCT was 160 microns (SD=48) and the mean axial length was 23.2mm (SD=0.93). In an age-matched control group of 25 patients undergoing cataract surgery, the mean SFCT was 156 microns (SD=38) and their mean axial length was 23.5mm (SD=0.93mm). There was no significant difference in the SFCT or axial length between the RAP eyes or controls ($p=0.8$ and 0.1 respectively).

The correlation (r_s) of SFCT measurements between the two observers for RAP eyes and control eyes and was 0.75 ($p<0.001$) and 0.92 ($p<0.001$) respectively.

Reading centre grading of the RAP lesions revealed that 3 (6%) were stage 1, 9 (20%) were stage 2 and 34 (74%) were stage 3. At baseline, the fellow eye had evidence of pre-existing nAMD or disciform scarring in 14 patients (30%). In one case, it was impossible to evaluate the fellow eye due to a long standing retinal detachment and dense cataract. Of the remaining 31 eyes, 13 (42 %) developed a new angiographically confirmed RAP lesion by week 96. No were instances of RPE rip during the study follow up period.

Mean BCVA improved by 6.0 (SD=7.9) and 4.8 (SD=7.4) ETDRS letters at 52 and 96 weeks respectively, from a baseline of 57.3 (SD=12.0) letters ($p=0.03$ and 0.02 respectively). The change in mean BCVA over time is shown in fig 1. The largest improvement in BCVA was seen early in the course of treatment with a peak of 8 letters gain at 20 weeks. At the 52 week time point, 45/46 (98%) of patients had maintained their vision (less than 15 letters of BCVA lost) while 10/46 (22%) of patients had gained 15 letters or more. At the 96 week time point, 41/46 (89%) of patients had maintained their BCVA while 13/46 (28%) of patients had gained 15 letters or more. Of the 5 patients who lost 15 letters or less at week 96, 4 were due to central foveal photoreceptor atrophy and 1 was due to extensive scarring after a sub macular haemorrhage.

The mean central macular thickness (CMT) reduced by 135 microns (SD= 118) at 4 weeks from a mean of 438 microns at baseline (SD=105) ($p<0.0001$). At 52 weeks, the mean CMT was reduced by 165 microns (SD=156) ($p<0.0001$), with 83 % of maculae being fluid free, while at week 96, there was a mean reduction in CMT of 162 microns (SD=106) ($p<0.0001$) with 72 % of maculae being fluid free. The change in mean CMT over time is shown in fig 2

Due to the small number of patients with a poor visual outcome, it was not possible to perform univariable or multivariable analyses to determine factors associated with a poor outcome. There were a larger number of patients with a favourable outcome (greater than a 15 letter gain in BCVA) and it was possible to perform univariable analysis on these patients. We found no evidence of an effect of age, sex, lesion stage at baseline, symptom duration prior to treatment, smoking, diabetic status or the presence of cardiovascular disease on a favourable visual outcome at weeks 52 and 96 (data presented in table2). The outcomes of the 2q8 View 2 study group and the current RAP cohort are compared in table 3. It can be seen that the proportion of patients with stable vision and those gaining more than 15 letters was similar in the 2 groups. There was no statistically significant difference for any of the visual outcomes of the current study and the 2q8 group in the View study ($p>0.05$ for all comparisons using Fisher's exact test). The mean number of injections required and the mean change in CMT in each group was also similar.

Conclusion

This study demonstrates that a fixed dosing schedule of aflibercept in the first year followed by a capped prn protocol in the second year, replicating that used in the pivotal View studies, was an effective treatment for type 3 neovascularisation or RAP. Our outcomes corroborate the results of the subgroup analysis of the CATT trial which showed that the outcomes of RAP lesions treated with either ranibizumab or bevacizumab were similar to more type 1 and 2 wet AMD lesions without RAP at 2 years, irrespective of the protocol or drug used¹⁸. Other prospective studies investigating the effect of the anti-VEGF agents ranibizumab and bevacizumab on RAP lesions have also demonstrated that these drugs appear to stabilise or improve visual acuity and reduce macular thickness at up to 2 years of follow up^{6,20,22,39}.

Aflibercept was approved in the UK for treatment of nAMD in 2013. It has a higher affinity for VEGF-A, a longer half-life, offering the hope of a longer duration of action and also blocks the action of placental growth factor. Because RAP lesions may represent an aggressive subtype of nAMD, with a potentially poor visual prognosis, it was suggested that these properties of aflibercept may be useful in the treatment of RAP²⁶. In 2014, Tsaousis et al were the first to show that aflibercept may be beneficial in treating RAP lesions by presenting the 4 month follow up results of 12 eyes with stage 1 and 2 RAP lesions treated with 3 monthly loading doses of aflibercept²⁶. They found a 0.14 logMAR improvement in BCVA and a significant reduction in CMT. The study was limited by short follow up and small patient numbers. A larger prospective study on the effect of aflibercept, published in 2015 by Oishi et demonstrated that in a small sub group of AMD patients diagnosed with RAP, who were treated as per the VIEW study year 1 protocol, there was a non-significant improvement in BCVA²⁸. Finally, a significant improvement in BCVA and reduction of CMT at 12 months was shown in a small retrospective study of 17 patients published in 2016 by Matsumoto et al, in which patients were subjected to a loading phase with

aflibercept, followed by a treat and extend phase of treatment²⁷. Unfortunately to date, there are no published prospective, large-scale clinical studies of intravitreal aflibercept using a treat and extend regimen in nAMD, although this may change in the future ⁴⁰.

Our study demonstrated a rapid improvement in vision after treatment initiation, reaching a peak of 8 ETDRS letters at week 24 while maximum CMT reduction was seen at week 8. Interestingly, the mean CMT reduction was less between weeks 16 and 48 which coincides with the period of bimonthly treatment. After this period, the capped prn protocol, re-establishes the maximum reduction in CMT. This would indicate that during the bimonthly period, the lesions retain some residual activity and that bimonthly treatment may be suboptimal. This theory is given added credence when one looks at the study of Kim et al⁴¹. Although the study was retrospective in nature and most patients received ranubizumab instead of aflibercept, they used an essentially prn protocol after an initial loading phase for 12 months. They found a significantly worse outcome for stage 3 lesions (even when dry on OCT) compared with stage 2 lesions. Compared with our study in which all patients received 8 aflibercept injections in the first 12 months, their cases received 4.2 and 4.6 injections for stage 2 and 3 lesions respectively. Three out of 26 (12%) of their stage 3 lesions also developed visually significant RPE rips during follow up compared with no RPE rips in the current study. Based on our findings, this would suggest that the stage 3 lesions were undertreated in their study and provides further evidence that RAP lesions require intensive treatment at least during the first 12 months of follow up.

Despite the maintenance of maximum CMT reduction after week 48, BCVA gain gradually declines from 8 letters at week 24 to 4.9 letters at week 96. The reason for this decline is unknown, but may be due to progressive RPE atrophy, which is known to be more commonly associated with RAP lesions ^{42,43} or the accumulation of photoreceptor damage caused by earlier sub optimal treatment.

In the current study, the percentage of eyes with stable vision and gaining 15 or more letters and the number of injections given over 2 years were similar between

this study and the View trial²⁵. Interestingly, more patients were fluid free at week 96 in the RAP cohort compared with VIEW non-RAP lesions (74% vs 50%). This finding was also found in the CATT subgroup analysis¹⁸. Like other researchers, we found that patients with RAP were older and were more likely to have reticular pseudodrusen at baseline compared with type 1 and 2 wet AMD patients. Unlike other researchers, we found no difference in the subfoveal choroidal thickness at baseline between our RAP patients and age matched controls, however, our patients were of a different racial group compared with those previously published^{44,45}. In comparison to other researchers, we found no association of favourable treatment outcome with lesion stage⁴⁶ or with symptom duration prior to treatment as seen in type 1 and 2 nAMD⁴⁷. This may be due to the effect of the skewed distribution of lesion stages within our group (most were stage 3) and/or relatively small patient numbers. Baseline smoking status, diabetes or the presence of pseudophakia, also appeared not to affect visual outcome. In a recent post hoc analysis of the visual outcomes of the VIEW studies, better visual gain was associated with younger age, worse initial vision, smaller CNV size and certain CNV subtypes at baseline³³. Interestingly, no RAP lesions were reported to be included in this analysis of the VIEW study, even though they would be expected to make up approximately of cases of nAMD.

In cases of unilateral RAP, we found that a similar lesion developed in the fellow eye in 42% of cases by week 96. This is similar to the results reported Gross et al, who found 52% of patients developed RAP in the fellow eye by 2 years⁹.

This study has the strengths that it is the largest series to date of treatment naïve RAP patients undergoing prospective treatment with aflibercept. In addition, all patients were reviewed within the timescales of the VIEW protocol and also underwent BCVA logMAR measurement at each visit. The diagnosis of RAP was also confirmed and graded by an independent reading centre. Disadvantages include the absence of a true control group and the relatively small number of patients recruited which reduces the power to detect an effect of baseline demographics and lesion characteristics on outcomes. In summary we present the long term results of the largest series to date of patients treated prospectively with aflibercept for RAP and show that they benefit from treatment to a similar degree to those with type 1 and 2 nAMD up to week 96³³.

Legends

Fig 1. Mean change in best corrected visual acuity (BCVA) from baseline to week 96.

Fig 2. Mean change in central macular thickness (CMT) from baseline to week 96

Acknowledgments: None

Disclosure Statement:

Andrew C. Browning: No conflicts of interest

Jill M. O'Brien: No conflicts of interest

Rute V. Vieira: No conflicts of interest

Rajen Gupta: honorarium and travel grant from Bayer

Kapka Nenova: honorarium and travel grant from Bayer

Ethics Statement:

Subjects have given their written informed consent and the study protocol has been approved by the research institute's committee on human research.

References

1. Yanuzzi LA, Negrao S, Iida T et al. Retinal angiomatous proliferation in age-related macular degeneration. *Retina* 2001;21:416-434.

2. Yannuzzi LA, Bailey Freund K, Takahashi BS, LuEsther T. Review of retinal angiomatous proliferation or type 3 neovascularization. *Retina* 2008;28:375-384.
3. Freund KB, Ho IV, Barbazetto IA, et al. Type 3 neovascularization: the expanded spectrum of retinal angiomatous proliferation. *Retina*. 2008;28:201-211.
4. Lafaut BA,S, Vanden Broeke C, Bartz-Schmidt. Clinicopathological correlation of deep retinal vascular anomalous complex in age related macular degeneration. *Br J Ophthalmol* 2000;84:1269-1274.
5. Sawa M, Ueno C, Gomi F, Nishida K. Incidence and characteristics of neovascularization in fellow eyes of Japanese patients with unilateral retinal angiomatous proliferation. *Retina*. 2014;34:761-767.
6. Shin JY, Yu HG. Optical coherence tomography-based ranibizumab monotherapy for retinal angiomatous proliferation in Korean patients. *Retina* 2014;34:2359-2366.
7. Caramoy A, Ristau T, Lechanteur YT et al. Environmental and genetic risk factors for retinal angiomatous proliferation. *Acta Ophthalmol* 2014;92:745-748.
8. Wegscheider BJ, Weger M, Renner W, et al. Association of complement factor H Y402H gene polymorphism with different subtypes of exudative age-related macular degeneration. *Ophthalmology*. 2007;114(4):738-742.
9. Gross NE, Aizman A, Brucker A, Klancnik JM, Yannuzzi LA. Nature and risk of neovascularization in the fellow eye of patients with unilateral retinal angiomatous proliferation. *Retina*. 2005;25:713-718.
10. Viola F, Massacesi A, Orzalesi N, Ratiglia R, Staurenghi G. Retinal angiomatous proliferation Natural history and progression of visual loss. *Retina* 2009;29:732-739.
11. Campa C, Harding SP, Pearce IA et al. Incidence of neovascularisation in the fellow eye of patients with unilateral retinal angiomatous proliferation. *Eye* 2010;24:1585-1589.

12. Shiragami C, Iida T, Nagayama D, Baba T, Shiraga F. Recurrence after surgical ablation for retinal angiomatous proliferation. *Retina* 2007;27:198-203
13. Johnson TM, Glaser BM. Focal laser ablation of retinal angiomatous proliferation. *Retina*. 2006;26:765-772.
14. Kuroiwa S, Arai J, Gaun S, Iida T, Yoshimura N. Rapidly progressive scar formation after transpupillary thermotherapy in retinal angiomatous proliferation. *Retina* 2003;23(3):417-420.
15. Bottoni F, Massacesi A, Cigada M, Viola F, Musicco I, Staurenghi G. Treatment of retinal angiomatous proliferation in age-related macular degeneration: a series of 104 cases of retinal angiomatous proliferation. *Arch Ophthalmol*. 2005;123:1644-1650.
16. Boscia F, Parodi MB, Furino C, Reibaldi M, Sborgia C. Photodynamic therapy with verteporfin for retinal angiomatous proliferation. *Graefes Arch Clin Exp Ophthalmol*. 2006;244:1224-1232.
17. Montero JA, Ruiz-Moreno JM, Sanabria MR, Fernandez-Munoz M. Efficacy of intravitreal and periocular triamcinolone associated with photodynamic therapy for treatment of retinal angiomatous proliferation. *Br J Ophthalmol*. 2009;93:166-170.
18. Daniel E, Shaffer J, Ying GS, et al. Outcomes in Eyes with retinal angiomatous proliferation in the Comparison of Age-Related Macular Degeneration Treatments Trials (CATT). *Ophthalmology*. 2016;123:609-616.
19. Cho HJ, Lee TG, Han SY, et al. Long-term visual outcome and prognostic factors of intravitreal anti-vascular endothelial growth factor treatment for retinal angiomatous proliferation. *Graefes Arch Clin Exp Ophthalmol* 2016;254:23-30.
20. Altmani K, Voigt M, Le Tien V et al. Ranibizumab for retinal angiomatous proliferation in age-related macular degeneration. *Eye* 2010;24:1193-1198.

21. Engelbert M, Zweifel SA, Bailey Freund K. Treat and extend dosing of intravitreal anti-vascular endothelial growth factor therapy for type 3 neovascularization/retinal angiomatous proliferation. *Retina* 2009;29:1424-1431.
22. Gharbiya M, Parisi F, Cruciani F, Bozzoni-Pantaleoni F, Pranno F, Abdolrahimzadeh S. Intravitreal anti-vascular endothelial growth factor for retinal angiomatous proliferation in treatment-naive eyes: long-term functional and anatomical results using a modified PrONTO-style regimen. *Retina*. 2014;34:298-305.
23. Rouvas AA, Chatziralli IP, Theodossiadis PG, Moschos MM, Kotsolis AI, Ladas ID. Long-term results of intravitreal ranibizumab, intravitreal ranibizumab with photodynamic therapy, and intravitreal triamcinolone with photodynamic therapy for the treatment of retinal angiomatous proliferation. *Retina*. 2012;32:1181-1189.
24. Heier JS, Brown DM, Chong V et al. Intravitreal aflibercept (VEGF Trap-eye) in wet age-related macular degeneration. *Ophthalmology* 2012;119:2537-2548.
25. Schmidt-Erfurth U, Kaiser PK, Korobelnik JF et al. Intravitreal aflibercept injection for meovascular age related macular degeneration Ninety six-week results of the VIEW studies. *Ophthalmology* 2014;121:193-201.
26. Tsaousis KT, Konidaris VE, Banerjee S, Empeslidis T. Intravitreal aflibercept treatment of retinal angiomatous proliferation: a pilot study and short term efficacy. *Graefes Arch Clin Exp Ophthalmol* 2015;253:663-665.
27. Matsumoto H, Sato T, Morimoto M, et al. Treat-and-extend regimen with aflibercept for retinal angiomatous proliferation. *Retina*. 2016;36:2282-2289.
28. Oishi A, Tsujikawa A, Yamashiro K, et al. One-year result of aflibercept treatment on age-related macular degeneration and predictive factors for visual outcome. *Am J Ophthalmol*.2015;159:853-860.

29. National Institute for health and care Excellence. Aflibercept solution for injection for treating age related macular degeneration. Published date July 2013. Available from <http://www.nice.org.uk/guidance/ta294>.
30. National Institute for health and care Excellence. Ranibzumab and pegaptanib for the treatment of age related macular degeneration. Updated July 2012. Available from <http://www.nice.org.uk/guidance/ta155>.
31. Slakter JS, Yannuzzi LA, Schneider U, et al. Retinal choroidal anastomoses and occult choroidal neovascularization in age-related macular degeneration. *Ophthalmology*. 2000;107:742-753.
32. Rouvas AA, Papakostas TD, Ntouraki A, Douvali M, Vergados I, Ladas ID. Angiographic and OCT features of retinal angiomatous proliferation. *Eye* 2010;24:1633-1642.
33. Lanzetta P, Cruess AF, Cohen SY et al. Predictors of visual outcomes in patients with neovascular age-related macular degeneration treated with anti-vascular endothelial growth factor therapy: post hoc analysis of the VIEW studies. *Acta Ophthalmol* 2018;96:911-918.
34. Brown DM, Kaiser PK, Michels M et al. Ranibizumab versus Verteporfin for Neovascular Age-Related Macular Degeneration. *N Engl J Med* 2006;355:1432-1444.
35. Zarubina AV, Neely DC, Clark ME, et al. Prevalence of subretinal drusenoid deposits in older persons with and without age-related macular degeneration, by multimodal imaging. *Ophthalmology*. 2016;123:1090–1100.
36. De Bats F, Mathis T, Mauget-Faysse M et al. Prevalence of reticular pseudodrusen in age-related macular degeneration using multimodal imaging. *Retina*. 2016;36:46–52.
37. Age-Related Eye Disease Study Research Group. The Age-Related Eye Disease Study system for classifying age-related macular degeneration from stereoscopic color fundus photographs: the Age-Related Eye Disease Study Report Number 6. *Am J Ophthalmol*. 2001;132:668-81.

38. Peduzzi, P, Concato J, Kemper E, Holford TR. and Feinstein AR. A Simulation Study of the Number of Events per Variable in Logistic Regression Analysis. *Journal of Clinical Epidemiology* 1996;49: 1373-1379.
39. Parodi MB, Iacono P, Menchini F et al. Intravitreal bevacizumab versus ranibizumab for the treatment of retinal angiomatous proliferation. *Acta Ophthalmol*,2013;91:267-273.
40. Wai KM, Singh RP. Treat and extend dosing regimen with anti-vascular endothelial growth factor agents for neovascular age-related macular degeneration. *Am J Ophthalmic Clin Trials* 2018 in press.
41. Kim JH, Cnaahg YS, Kim JW, Kim CG, Lee DW, Cho SY. Difference in treatment outcomes according to optical coherence tomography-based stages in type 3 neovascularisation (retinal angiomatous proliferation) *Retina* 2018;38;2356-2362.
42. Han JC, Seul GY, Hyoung SK et al. Risk factors for geographic atrophy after intravitreal ranibizumab injections for retinal angiomatous proliferation. *Am J ophthalmol* 2015;159:285-292.
43. Baek J, Jae HL, Jun YK et al. Geographic atrophy and activity of neovascularization in retinal angiomatous proliferation. *Invest Ophthalmol Vis Sci* 2016;57:1500-1505.
44. Kim JH, Kim JR, Kang SW, Kim SJ, Ha HS. Thinner choroid and greater drusen extent in retinal angiomatous proliferation than in typical exudative age-related macular degeneration. *Am J Ophthalmol* 2013;155:743-749.
45. Yamazaki T, Koizumi H, Yamagashi T, Kinoshita S. Subfoveal choroidal thickness in retinal angiomatous proliferation. *Retina* 2014;34:1316-1322.
46. Frutos JR, Calvo-Gonzalez C, Perez-Trigo S et al. Ranibizumab in retinal angiomatous proliferation(RAP): influence of RAP stage on visual outcome. *Eur J Ophthalmol* 2011;21:783-788.

47. Lim JH, Wickremasinghe SS, Xie J et al. Delay to treatment and visual outcomes in patients treated with anti-vascular endothelial growth factor for age-related macular degeneration. *Am J Ophthalmol* 2012;153:678-686.

Table 1. Comparison of the demographics and baseline characteristic of the 2q8 View study and the current RAP cohort.

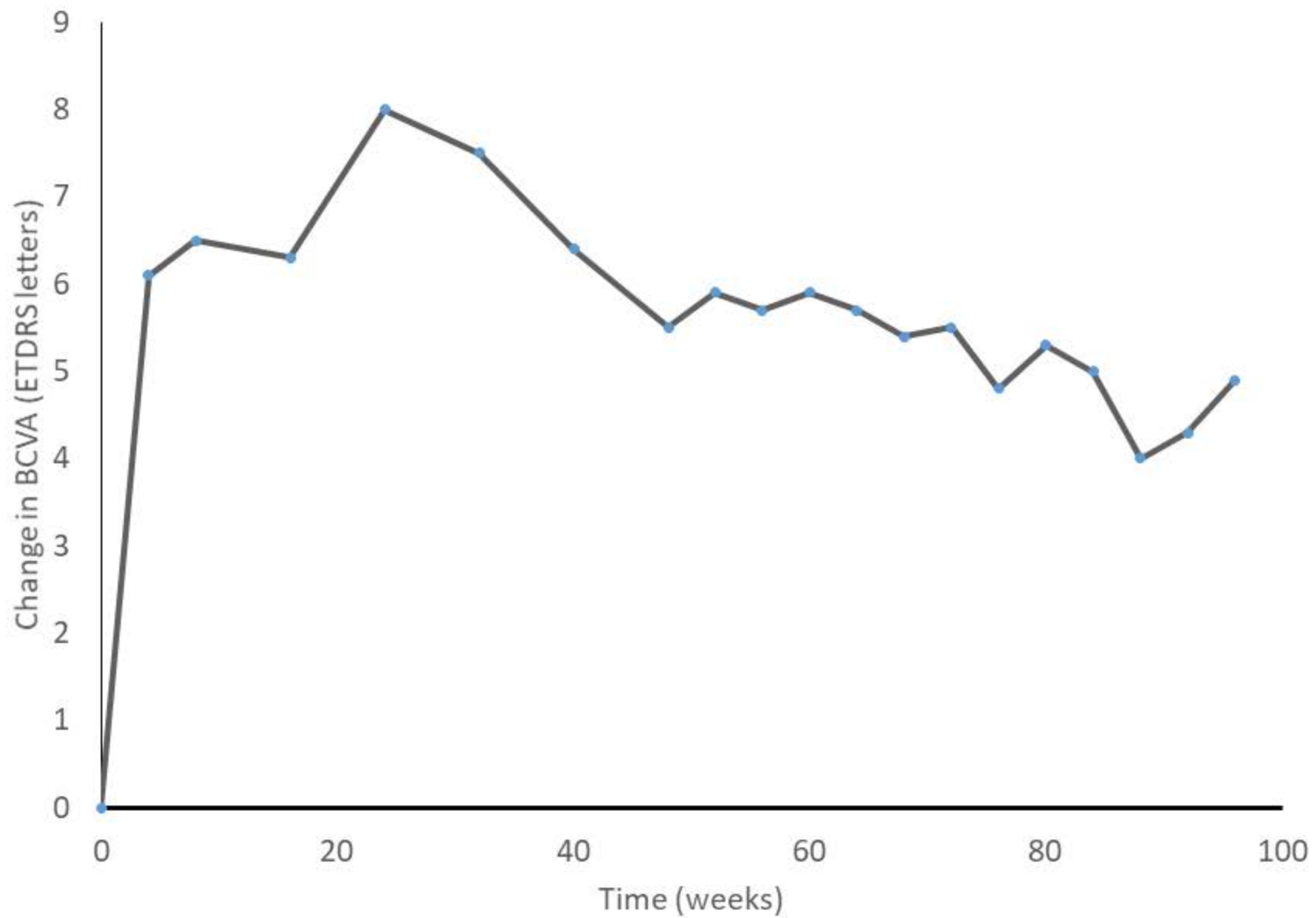
	View study	RAP cohort
Number	607	46
Mean age (yrs)	75.8	81.5
Race % (white)	83	100
Sex %		
Men	41.8	26
Women	58.2	74
Baseline BCVA (ETDRS letters)	53.6	57.3
Mean CMT (microns)	306	438

Table 2 Results of the univariable analysis on the relationship between a 15 letter gain in BCVA and the individual baseline demographics. Odds ratios that include 1 are not statistically significant

Variable	Category	OR (week 52)	95%CI	OR (week 96)	95% CI
Age	per year	0.97	0.87-1.07	0.98	0.89-1.07
Sex	female	1.0		1.0	
	Male	1.29	0.24-5.79	0.8	0.15-3.37
Smoking	yes	1.78	0.32-8.39	1.11	0.21-4.94
RAP stage	1	1.0		1.0	
	2	0.25	0.01-8.2	0.62	0.05-14.3
	3	0.57	0.03-16.1	0.83	0.07-19.1
Symptom					
Duration	per week	0.99	0.89-1.06	1.0	0.93-1.07
Diabetic	No	1.0		1.0	
	yes	1.55	0.2-8.8	2.18	0.38-11.62
Cardiovascular					
Disease	no	1.0		1.0	
	Yes	0.5	0.07-2.39	1.02	0.23-4.0
Hypertension	no	1.0		1.0	
	Yes	1.07	0.26-4.8	1.18	0.32-4.63
Reticular					
Pseudo drusen	no	1.0		1.0	
	Yes	1.8	0.26-36.3	2.67	0.39-53.3
Clopidogril	no	1.0		1.0	
	Yes	0.89	0.04-7.0	0.6	0.03-4.6

OR: odds ratio; CI: confidence interval.

	VIEW study (2q8 group)		RAP study	
	wk 52	wk 96	wk 52	wk96
Number of pts with stable vision (%)	95	92	98	89
Injections	7	4.2	8	4.9
Fluid free on OCT (%)	68	50	83	72
Number of patients gaining 15 letters or more (%)	31	33	22	28
Mean CMT change from baseline (microns)	139	133	165	162



Time (weeks)

